

Comparison of Different Knee Implants Used on Patients with Osteoarthritis Control Study

BOGDAN ANDOR¹, JENEL M. PATRASCU¹, SORIN FLORESCU^{1*}, DAN COJOCARU³, MIHAI SANDESC³, FLORIN BORCAN^{2*}, OVIDIU BORUGA⁴, SORIN BOLINTINEANU⁵

¹ Victor Babes University of Medicine and Pharmacy Timisoara, Faculty of Medicine, Department of Orthopaedic II, 2 Eftimie Murgu Sq., 300041, Timisoara, Romania

² Victor Babes University of Medicine and Pharmacy Timisoara, Faculty of Pharmacy, Department of Analytical Chemistry, 2 Eftimie Murgu Sq., 300041, Timisoara, Romania

³ Emergency County Hospital Pius Branzau Timisoara, Department of Orthopaedic II, 10 Iosif Bulbuca Blvd. 300736, Timisoara, Romania

⁴ Victor Babes University of Medicine and Pharmacy Timisoara, Faculty of Medicine, Department of Ophthalmology, 2 Eftimie Murgu Sq., 300041, Timisoara, Romania

⁵ Department of Anatomy, Faculty of Medicine, Victor Babes University of Medicine and Pharmacy Timisoara, 2 Eftimie Murgu Sq., 300041, Timisoara, Romania

The field of cartilage repair and restoration has expanded a lot in the last decade since articular cartilage problems are very common. As a consequence, many biomaterials were created in order to aid physicians in treating different osteochondral defects. Polymers like polyurethanes or PGA-hyaluronan have been frequently used as the in vivo cartilage tissue repair solution, as reported in animal studies and in clinical applications. Three different implants (Agili-C, Hyalograft C, and Chondrotissue) were used in 23 patients (6 medial and 17 lateral lesions) in this study. Patients were assessed at 3, 6, 9, and 12 months postoperative follow-up visits using the International Knee Documentation Committee (IKDC) scores and Knee injury and Osteoarthritis Outcome Score (KOOS). The follow-up assessments demonstrated clinically and statistically significant improvements ($p < 0.05$) in all clinical outcome scores, as compared to the respective preoperative values: IKDC (48.9/77.1 for Chondrotissue implants), KOOS symptoms (58.2/71.9 for Agili-C implants), KOOS pain (54.8/66.1 for Agili-C implants), KOOS daily living activities (64.2/76.3 for Agili-C implants), KOOS sports (38.3/60.8 for Agili-C implants), KOOS quality of life (40.1/60.7 for Agili-C implants) demonstrating improvements in the case of implants previously mentioned. The overall results of this study support the successful use of the Agili-C, Chondrotissue and Hyalograft-C implants for the treatment of knee cartilage lesions.

Keywords: cartilage repair, implants, IKDC, KOOS, Agili-C, Chondrotissue, Hyalograft-C.

Articular cartilage lesions of the knee (fig. 1) are often caused by joint trauma and are diagnosed with increasing frequency [1-3]. Chondral or osteochondral defects have been reported in 60% [4] to 67% [5] of patients in studies reporting knee arthroscopies.

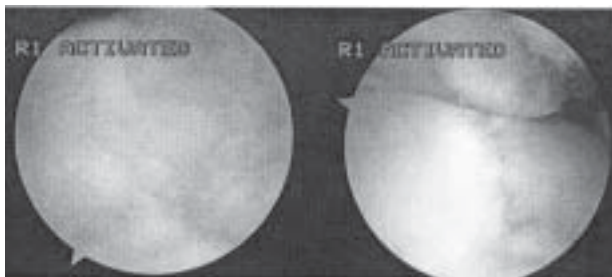


Fig. 1. Cartilage lesion

Osteochondral defects are often symptomatic and adversely affect the functionality of the joint. The spontaneous healing capacity of osteochondral defects is limited. Left untreated, these lesions lead to tissue degeneration and eventually to progressive loss of functionality.

Full-thickness chondral and osteochondral lesions often

trigger or set off symptoms such as recurrent joint locking, effusion, and marked pain. These symptoms are frequently responsible for a significant reduction in quality of life and physical exercise performance, especially sports activities.

The choice of treatment usually is based on the size, depth, and location of the defect.

Bone marrow-stimulating techniques such as Pridie drilling [6] or microfracturing [7] are frequently used as the first-line surgical procedure. Limitations of these techniques are poor repaired tissue quality, ranging from hyaline to fibrous cartilage [8], and a decrease of clinical scores in patients who are 40 years old or younger at 18 to 36 months follow-up [9].

During recent decades, the principal procedures used for the treatment of focal cartilage lesions have been debridement, bone-marrow stimulation through microfractures, osteochondral autografts, osteochondral allografts, or the implantation of autologous chondrocytes, acellular scaffolds capable of induction of mesenchymal stem-cell migration. Tissue scaffolding has gained popularity and interest during the past decades (fig. 2 and 3).

A wide range of biomaterials has been proposed [2, 5, 10, 11, 25, 27, 28]. Polymers like PGA-hyaluronan used for

* email: florescusorin@yahoo.com; Tel.: 0040744634184; fborcan@umft.ro; Tel.: 0040722371025

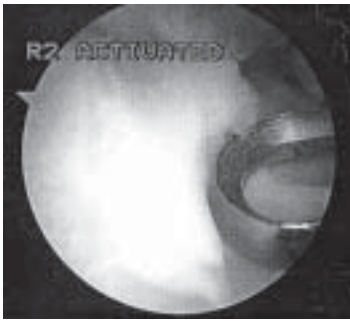

Fig. 2. Cleaning of receptor area

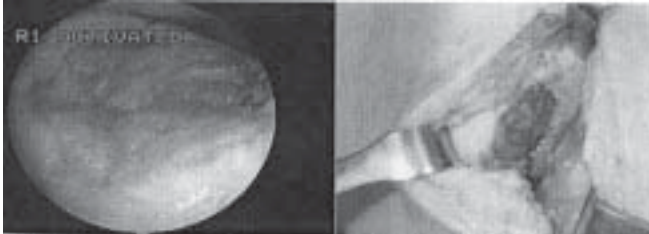


Fig. 3. Implantation by graft direct application through joint movement

in vivo cartilage tissue repair reportedly gave rise to hyaline cartilage in animal studies [12, 13] and in clinical applications [10, 11].

Polyurethanes (PU) are produced by mixing two or more liquid streams, generally an organic component (diisocyanate) and an aqueous component (mixture of diols, polyols, and a catalyst). PU can be synthesized with a large range of densities and toughness by varying the raw materials and their ratios. PUs are often used as medical materials due to their processing versatility, biocompatibility, flexural endurance, and high strength. J. Defrere and A. Franckart studied the teflon/polyurethane arthroplasty of the knee on 23 patients [14]; they had clinical and radiographic follow-ups at a minimum period of 2 years after implantation and concluded that this composite implant has been successful as a prosthetic knee resurface implant and that it demonstrates good biocompatibility. A recent study revealed the successful treatment of painful irreparable partial meniscal defects with a polyurethane scaffold [15, 28]; fifty-two patients were monitored for 2 years after implantation using MRI technique, KOOS and Lysholm scores and stable or improved values were observed in more than 90% of patients between baseline and 24 months.

Since 2005, in the Orthopaedics and Traumatology Clinic II of Timisoara the following methods of osteochondral lesions repair were used:

1. Agili-C is a novel, biphasic osteochondral implant composed of modified aragonite and hyaluronic acid. The implant is acellular, biodegradable, capable of bone-marrow mesenchymal stem-cell recruitment, preclusive of inappropriate fibroblastic ingrowth, and capable of facilitating functional hyaline cartilage and bone regeneration. Previous large-animal implantation studies have indicated that the implant is degraded *in vivo* and undergoes replacement by mesenchymal stem cells without an inflammatory component.

2. Autologous cartilage using a technique with tridimensional solid support (HYAFF-11) Hyalograft C. This is an innovative tissue-engineering approach for the treatment of knee cartilage defects involving the implantation of laboratory expanded autologous chondrocytes grown on a three-dimensional hyaluronan-based scaffold. Because no periosteal coverage is required to keep the graft in place, surgical time and morbidity are reduced. This technique is used for the following

applications: 3rd-4th grade chondral injuries (more than 2 cm²), without subchondral severe lesions, trauma lesions, and multiple injuries. It is not indicated for mirror cartilage lesions and degenerative lesions.

The procedures implies the following steps: (i) biopsy processing, (ii) cellular expansion in plastics, and (iii) informing the surgeon about the perfect moment for implantation surgery on the 7th day.

3. Autologous implant of chondrocytes using the arthroscopic pathway - Chondrotissue (BioTissue AG, Zurich, Switzerland) - collagen sterile matrix chondrotissue - absorbable non-woven polyglycolic acid textile treated with hyaluronic acid.

The chondrotissue[®] scaffold is an absorbable non-woven felt of pure PGA combined with fermentative and freeze-dried hyaluronic acid (average molecular weight, 1200 kDa) and a porosity of approximately 70%. According to the manufacturer, within 7 days, the scaffold loses 50% of the mechanical stability in liquids and generally shows complete absorption in as many as 60 days.

The matrix is like a sponge and retains the clot and the progenitor cells inside the defect, inducing hemostasis and protecting the subjacent tissue. The mechanical stability ensures handling and safe fixation by glue with fibrin, transosseous or trans-cartilage suture or absorbable brooches.

The mesenchymal stem cells derived from bone marrow are flushed into the cartilage defect by the scaffold, while their differentiation into chondrocytic cells is supported by the hyaluronic acid. The textile implant is a one-step procedure, is easy to handle and can be securely fixed to the defect. The matrix structure allows defects which lack an intact cartilage rim to be treated with the microfracture technique. In the ovine model, the combination of an absorbable textile scaffold and hyaluronan have been shown to accelerate and improve repair with cartilage matrix rich in type II collagen, compared with microfracture alone [4, 16, 26, 27,]. The combination of microfracture and chondrotissue is a promising option for the treatment of large cartilage defects. The results suggest that this technique may improve the quality of chondral repair. However, further prospective, comparative studies are needed.

Experimental part

In this study, 23 patients who had implantation by mini arthroscopy with 3 different implants for articular cartilage defects of the knee were reviewed: 13 patients with Agili-C implant (Cartiheal Ltd, Israel Implant), 3 patients with HYAFF-11- HYALOGRAFT-C, and 7 patients with Chondrotissue (BioTissue AG, Zurich, Switzerland) (Table 1). Patients were assessed by MRI imaging, IKDC and KOOS scores, and physical evaluations. At 3, 6, 9 or 12 months follow up, we reassessed IKDC and KOOS scores, MRI imaging, as well as physical evaluation. For one patient we also performed histologic staining in specimens obtained from a second look arthroscopy procedure.

None of the patients had any contraindication for the techniques. Three patients had associated Anterior Cruciate Ligament rupture which was resolved in the same intervention with the cartilage repair. All interventions were performed by the same surgical team. For arthroscopic surgery, an one-step procedure with anteromedial and anterolateral portals was used. Arthroscopy was performed with the patient in the supine position, and was performed for exploration and to resolve the ACL lesions. The cartilage repair was performed through mini arthrotomy (figs. 4-6).

For the patients that received the Agili-C implant, a

Characteristic	Patient data
Sex	female (n=9), male (n=14)
Age (years)	31.1 (range, 20-40)
Body mass index (kg/m ²)	25.8 (range, 21.9-33.2)
Knee	left (n=8), right (n=15)
Outerbridge classification, lesion grade	III (n=10), IV (n=13)
Localisation of lesion	medial (n=6), lateral (n=17)
Type of implant	cartiheel (n=13), Hyalograft (n=7), chondrotissue (n=3)
Type of intervention	arthrotomy (n=11), miniarthrotomy (n=7), microfractures covered with chondrotissue (n=3), arthrotomy and arthroscopic ligamentoplasty (n=2)
Previous surgical procedures	none

Table 1
CHARACTERISTICS OF THE PATIENTS

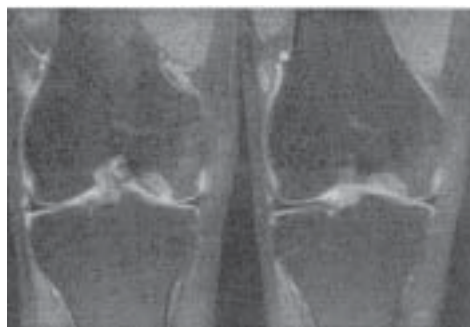

Fig. 4. Cartilage defect in the medial femoral condyle

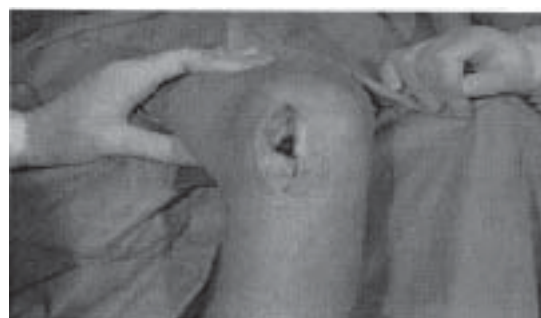

Fig. 6. The control of stability

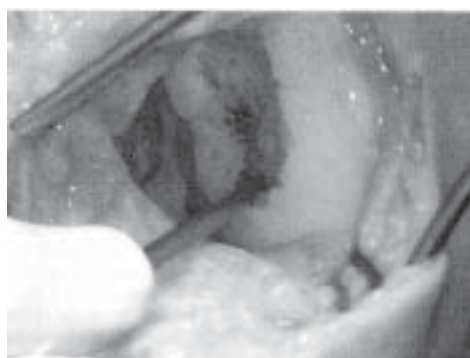


Fig. 5. Performing the microfractures

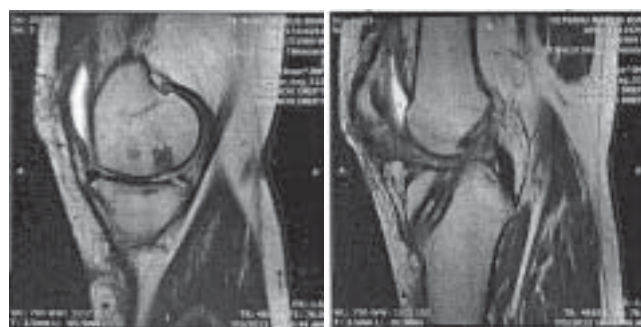


Fig. 7A. Cartilage defect resolved with AgiliC implant

Fig. 7B. Associated ACL lesion (same patient) resolved with hamstring graft

special instrumentation from the Cartiheel Company was used (fig. 7A, 8B)

In the 3 cases resolved using Hyalograft C, the harvest of the cartilage cells was done in the first stage, followed by processing, and the surgeon was informed about the proper moment for implantation intervention in the 7th day. The implantation proceeded using a miniarthrotomy procedure.

A standard mini-open arthrotomy was used in patients receiving Chondrotissue implants. The defective cartilage was carefully debrided down to the subchondral bone. A standard microfracture procedure was then performed. A freeze-dried chondrotissue matrix was immersed in 3 mL autologous serum for ten minutes and placed into the defect, as described by Zimmerman et al. [17]. For transosseous fixation of the matrix, absorbable threads were secured with threefold knots to act as anchors to the subchondral bone.

Postoperative rehabilitation protocol

The rehabilitation treatment was the following:

- between 6-8 weeks postoperatively - no weight bearing (walk with crutches);
- between 6 weeks - 4 month postoperatively - progressive loading (20 kg) walking.

Physical exercises:

- after suture removal - pool exercises;
- exercises for ROM and isometric exercises for quadriceps muscle;

- up to 4 months postoperatively - exercises with Artromot for knee (optional);
- after 4 months postoperatively - exercises with stationary bike;
- after 6 months - jogging;
- after 9 months - full sport activities.

Statistics

Paired Student's t tests or One-way Anova followed by Bonferroni's post-tests were used to determine the statistical difference between various postoperative scores and the values of preoperative scores; *, ** and *** indicate $p < 0.05$, $p < 0.01$ and $p < 0.001$.

Results and discussions

All patients underwent repeated MRIs after surgery (fig. 8). All coronal and sagittal images were examined by one observer (DC) to assess defect filling, effusion, and bone marrow edema. We also performed physical examination of the patients to determine the range of motion and joint effusion. In 1 patient receiving Chondrotissue, a second-look arthroscopy was performed to assess repaired tissue quality and tissue integration. The defect was found to be filled with tough hyaline-like cartilage repair tissue.

The histologic evaluation showed homogenous tissue, rich in round-shaped cells. A small area of the superficial biopsy layer showed some fibrous tissue, while the remainder was a hyaline-like tissue with round chondrocytic cells, evenly distributed in the tissue, insular or forming clusters. A few flattened cells were presented.

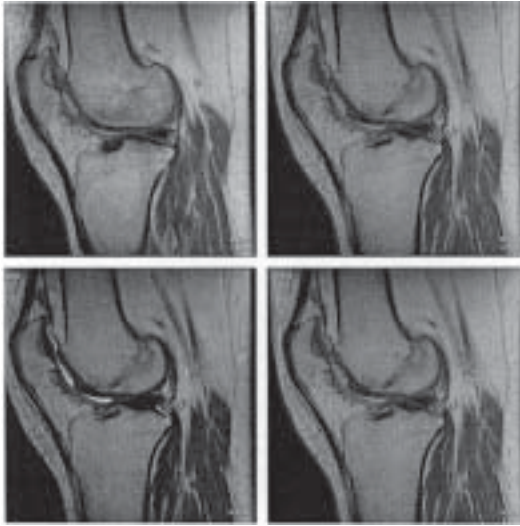


Fig. 8. MRI postoperative images for patients with Hyalograft C

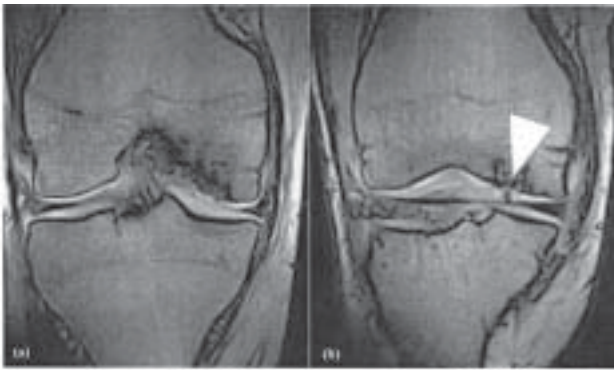


Fig. 9. MRI at 24 months follow-up on patient with Chondrotissue implant showing: (a) an excellent filling of defect, (b) uncovered crack adjacent to the cartilage edge

The deeper part showed chondral cell structures typical of hyaline cartilage. There were no signs of a foreign-body reaction, no infection, no allergic reaction and no abnormal calcification or formation of fibrous connective tissue. Neither necrosis of the tissue nor apoptosis of cells were evident. There was no residual chondrotissue matrix.

The MRI taken postoperatively in patients receiving Chondrotissue implants showed that the repair tissue was hyper- to iso-intensive compared to that of the surrounding cartilage. There was good integration of the repair tissue into the subchondral bone and the surrounding cartilage. Filling and covering of the defect was good to excellent (fig. 9).

Each patient was functionally and clinically evaluated using IKDC and KOOS scores at 3, 6, 9, and 12 months after surgery [18]. The KOOS is divided into subcategories for symptoms, pain, activities of daily living, sports and recreation function, and knee-related quality of life. We scored the five subcategories of KOOS separately: pain (9 items); symptoms (7 items); activities of daily living (17 items); sports and recreation (5 items), and quality of life (4 items).

Patient-reported measures of knee function are important for the comprehensive assessment of rheumatology conditions in both clinical and research contexts [19]. International Knee Documentation Committee (IKDC) score was designed as an evaluative measure to detect any improvement or deterioration in symptoms, function, and sports activity experienced by patients with a variety of knee conditions, including ligament and meniscal injuries, articular cartilage lesions, and patellofemoral pain [20]. K. Crawford's research team determined the psychometric properties of IKDC score for meniscus injuries of the knee using 445 patients divided in four groups; based on their results, it can be concluded

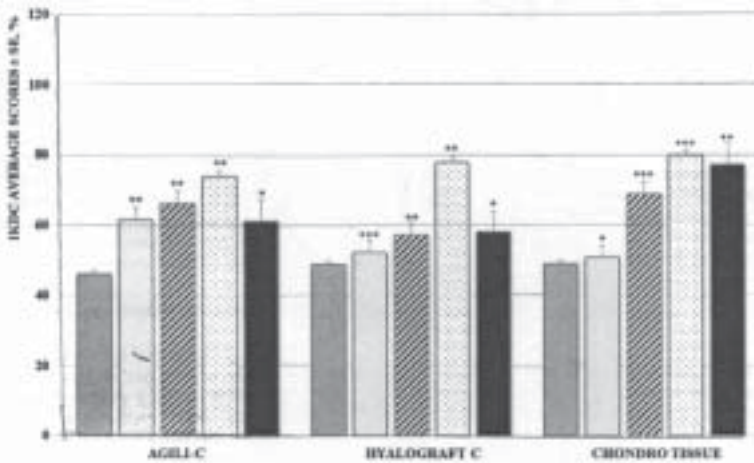


Fig. 10. Comparative evolution of IKDC average scores

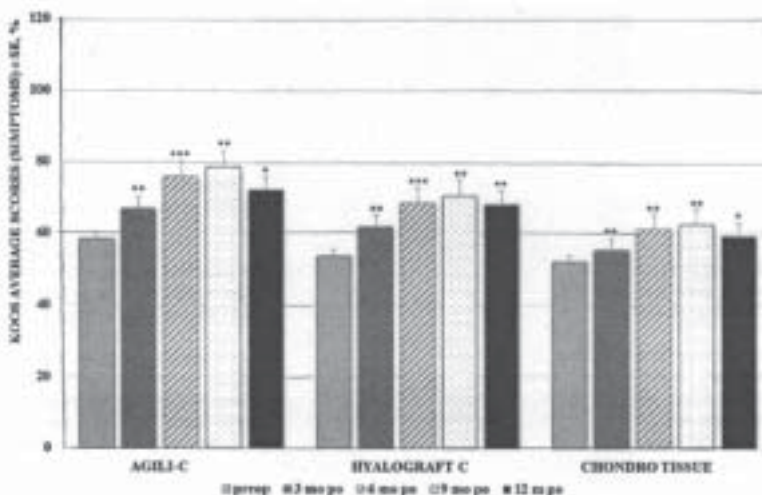


Fig. 11. Comparative evolution of KOOS average scores (symptoms)

that IKDC score showed overall acceptable psychometric performance for outcome measures of meniscus injuries of the knee [21].

In our study, the preoperative IKDC score was 47.82 ± 1.14 and the values increased for each implant in the first 9 months after implantation reaching an average value of 76.92 ± 2.88 units (fig. 10). An approximately linear increase in this period was recorded for Agili-C and Hyalograft C, while in the case of Chondrotissue an important increase was observed from the 3rd to 6th month postoperatively. For all three implant types, the IKDC values decreased slightly after the 9th month, compared to the 6th month values, probably due to the resuming of full sport activities. Patients treated with Chondrotissue displayed the smallest decrease. A. Gobbi and R. Francisco observed that a return to sports activities influences the IKDC score during a prospective clinical investigation on 100 athletes who underwent anterior cruciate ligament reconstruction with patellar tendon or hamstring tendon grafts [22].

The preoperative average value of KOOS symptoms for all 23 patients in this study was 54.60 ± 1.91 (fig. 11). Linear increases for each implant type were observed in the first nine months; thus, the average value increased to 70.41 ± 2.07 , and after that, it decreased to 66.33 ± 0.94 . It seems that the resumption of full sports activities affects the KOOS symptoms score as well. The KOOS symptoms value is a very important parameter used to evaluate the rehabilitation of patients with knee injuries; K. Hambly and K. Griva conducted a study on the differences between IKDC and KOOS scores and they found that KOOS outperformed the IKDC, even if the differences in individual items were not always evident [23].

Pain is an important symptom in many medical afflictions, and it may adversely impact the life quality of the patient [24]. The average value of KOOS pain increases

from a preoperative level 48.06 ± 2.46 to 74.15 ± 1.61 after 9 months, followed by a decrease to 64.36 ± 1.19 (fig. 12). The score increase trend was not linear over the first nine months post-implant period: a significant increase was observed in the first three months in patients treated with Agili-C implants, while the score increased more abruptly at 6 months postoperative in patients treated with the other two implants.

The evolution of average KOOS-daily living activity scores are summarized in figure 13. There were no non-linear increases in the first nine months postoperative period, similar to the evolution of the others scores. It is interesting to note that daily activity has improved more in the first three months and after that, there was a plateau in the scores. The average value increased from 56.97 ± 2.32 to a maximum level of 82.88 ± 2.48 units and then it decreased to 71.97 ± 2.14 . Even if this last value is lower, and thus less favorable, the overall ascendant trend indicates the good rehabilitation of all patients.

It is known that KOOS scores, which take approximately 10 min to evaluate, can be used to assess knee injuries that can result in post-traumatic osteoarthritis as anterior cruciate ligament, meniscus and/or chondral injuries. An advantage of these scores is the inclusion of two different subscales of physical function relating to daily life, sport, and recreation. In this study, the average value of KOOS sport was 38.44 ± 1.79 preoperatively, 61.67 ± 1.43 after 9 months, and 55.03 ± 1.12 after one year (Figure 14). The score increase trend from the first nine months after implantation was approximately linear for Hyalograft C and Chondrotissue implants, while a significant increase was observed in the first three months in the case of Agili-C implants.

In this study, the average preoperative KOOS-quality of life score was 39.74 ± 1.17 ; the values increased for each

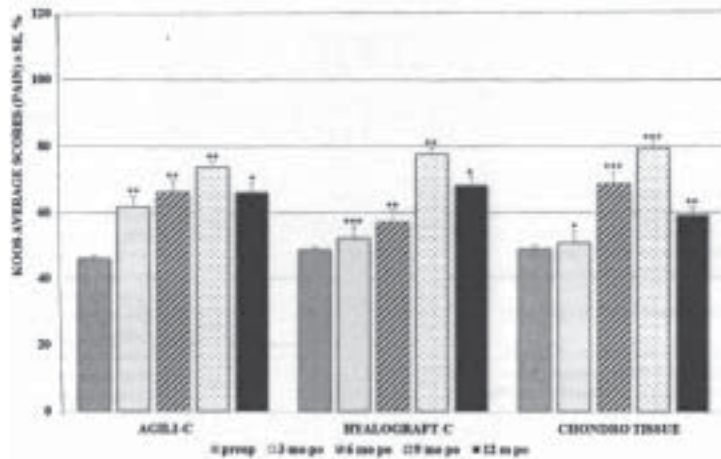


Fig. 12. Comparative evolution of KOOS average scores (pain)

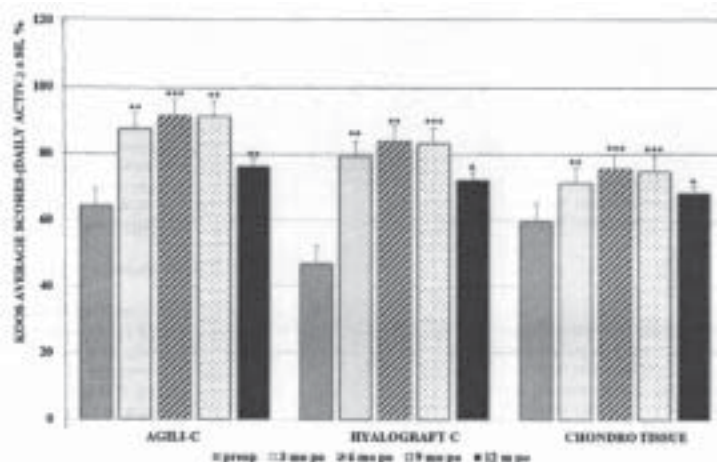


Fig. 13 - Comparative evolution of KOOS average scores (daily activ)

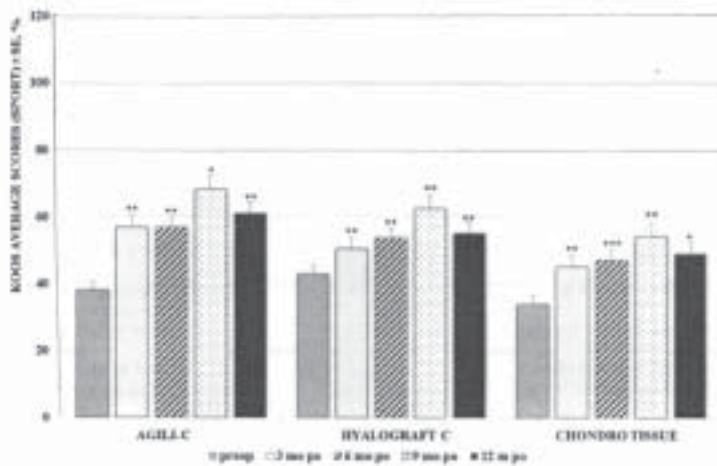


Fig. 14 .Comparative evolution of KOOS average scores (sport)

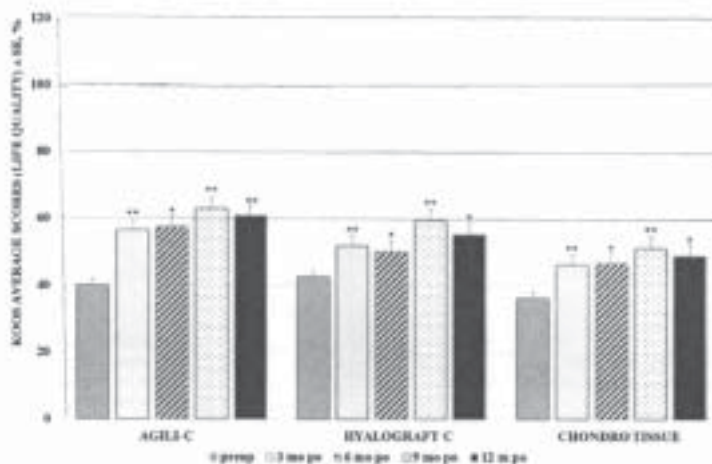


Fig. 15. Comparative evolution of KOOS average scores (quality of life)

implant type to a maximum level of 63.02 (Agili-C) after 9 months. It is interesting to note that all score values increased in the first 3 months and then they remained relatively constant or decreased slightly after 6 months postoperative; the scores then increase more in the following three months. Similar decreases were observed in the score evolution between 9-12 months post-intervention (fig. 15). Thus, the resumption of full intensity sports activities affect all the measured parameters.

Effusions were observed in 7 of the 23 patients at day 7, and reappeared at 3 months follow up in 3 of the patients. The effusions were resolved with no recurrence. During the year of follow up we identified no patients with debonding, thrombosis, infections, inflammation or allergic reactions. No patients required reoperation.

We solved the recovery associated injuries (meniscus and anterior cruciate ligament - anterior cruciate ligament) in the same intervention, but we believe it is better to first restore these injuries to ensure the stability of the knee and then perform another surgery to repair cartilage injury. This two-step procedure can lead to faster patient recovery by restoring cartilage.

The Chondrotissue and Agili-C implant interventions are single stage surgeries which can be performed both using miniarthrotomy and arthroscopy.

In the patients with Agili-C implants, MRI imaging studies showed complete tissue regeneration similar in signal to native hyaline cartilage and good bone integration and remodeling of the bony phase of the implants. Patients who received Agili-C implants had improved average KOOS as early as 3 months after surgery and at 6, 9, and 12 months postoperatively [25]. The IKDC average score improved from preoperatively to the last follow-up: 46 to 61 ($p < 0.05$). The average KOOS symptoms subcategory and pain

subcategory improved from preoperatively to the last follow-up: 58 to 72 ($p < 0.05$) and 55 to 66 ($p < 0.05$), respectively. Compared with the preoperative period, patients showed improvements daily living activities (64 to 76; $p < 0.01$), sports and recreational function (38 to 61; $p < 0.01$) and knee-related quality of life (40 to 61; $p < 0.01$) at 12 months postoperatively. All KOOS subcategories improved at 3 months postoperative, compared with the KOOS before surgery.

In the case of patients with Hyalograft-C implants, the IKDC average score also improved from the preoperative period to the last follow-up: 49 to 58 ($p < 0.05$). The average KOOS symptoms subcategory and pain subcategory improved as well during the same timeframe: 54 to 68 ($p < 0.01$) and 40 to 68 ($p < 0.05$), respectively. Compared with the time before surgery, patients showed improvements in daily living activities (47 to 72; $p < 0.05$), sports and recreational function (43 to 55; $p < 0.01$) and knee-related quality of life (43 to 55; $p < 0.05$) at 12 months postoperative.

The patients with chondrotissue implants presented an improved IKDC average score over the 12 month follow-up period: 49 to 77 ($p < 0.01$). The average KOOS symptoms subcategory and pain subcategory also improved: 52 to 59 ($p < 0.05$) and 49 to 59 ($p < 0.01$), respectively. Compared with the time before surgery, patients showed improvements daily living activities (60 to 68; $p < 0.05$), sports and recreation function activities (34 to 49; $p < 0.05$) and knee-related quality of life (36 to 49; $p < 0.05$) at 12 months postoperative.

This clinical study presented some minor limitations: (i) the IKDC and KOOS scores were limited to those obtained during a 12-month clinical follow-up period and we could not conclude on the long-term durability of these

implants; (ii) this was an uncontrolled observational case report study of 23 patients with focus on evaluation of clinical scores; thus we there was no control group; (iii) the histologic evaluation of the repair tissue was limited to specimens obtained from relatively few patients; MRIs were not used to evaluate all 23 patients; (iv) the cost effectiveness of these approaches was not studied; it is well known that, in developing countries, the treatment is also influenced by the costs.

All patients showed significant improvement at 12 months follow-up with no overt failures; however failure rates in cartilage and/or cartilage repair techniques do exist. Higher failure rates have been seen for Chondrotissue (7.2%) than for Agili-C (2.9%) or Hyalograft-C (3.2%) implants.

Conclusions

Agili-C, Hyalograft-C and Chondrotissue are three implants used frequently to repair knee lesions. In this study, the evolution of 23 patients was monitored using the International Knee Documentation Committee (IKDC) and Knee Injury and Osteoarthritis Outcome Score (KOOS) data. Our observations suggest that patients with Agili-C and Hyalograft-C present the best enhancements of IKDC and KOOS scores during a 12-month clinical follow-up.

Acknowledgements: This work was partially supported by the CEEF grant number 70/2006, "Innovative Bio-orthopaedics methods for articular reconstruction", contracted in collaboration with the "Victor Babes" University of Medicine and Pharmacy Timisoara.

References

1. ALSOUSOU J, THOMPSON M, HULLEY P, NOBLE A, WILLETT K: The biology of platelet-rich plasma and its application in trauma and orthopaedic surgery: a review of the literature. *J Bone Joint Surg Br* 2009, 91:987-996
2. BENTHJEN JP, BEHRENS P: Autologous matrix-induced chondrogenesis (AMIC): a one-step procedure for retropatellar articular resurfacing. *Acta Orthop Belg* 2010, 76:260-263
3. BRITTEBERG M, WINALSKI CS: Evaluation of cartilage injuries and repair. *J Bone Joint Surg Am* 2003, 85(suppl 2):58-69
4. HJELLE K, SOLHEIM E, STRAND T, MURI R, BRITTEBERG M: Articular cartilage defects in 1,000 knee arthroscopies. *Arthroscopy* 2002, 18:730-734
5. WILLIAMS CG, KIM TK, TABOAS A, MALIK A, MANSON P, ELISSEEFF J: In vitro chondrogenesis of bone marrow-derived mesenchymal stem cells in a photopolymerizing hydrogel. *Tissue Eng* 2003, 9:679-688
6. SCHMIDT H, HASSE E: Arthroscopic surgical treatment of circumscribed cartilage damage with spongification or Pridie drilling. *Beitr Orthop Traumatol* 1989, 36:35-37
7. STEADMAN JR, RODKEY WG, RODRIGO JJ: Microfracture: surgical technique and rehabilitation to treat chondral defects. *Clin Orthop Relat Res* 2001, 391(suppl):S362-S369
8. STEADMAN JR, BRIGGS KK, RODRIGO JJ, KOCHER MS, GILL TJ, RODKEY WG: Outcomes of microfracture for traumatic chondral defects of the knee: average 11-year follow-up. *Arthroscopy* 2003, 19:477-484
9. KREUZ PC, ERGGELET C, STEINWACHS MR, KRAUSE SJ, LAHM A, NIEMEYER P, GHANEM N, UHL M, SUDKAMP N: Is microfracture of chondral defects in the knee associated with different results in patients aged 40 years or younger? *Arthroscopy* 2006, 22:1180-1186
10. PATRASCU JM, FREYMAN U, KAPS C, POENARU DV: Repair of a post-traumatic cartilage defect with a cell-free polymer-based cartilage implant: a follow-up at two years by MRI and histological review. *J Bone Joint Surg Br* 2010, 92:1160-1163
11. ZANTOP T, PETERSEN W: Arthroscopic implantation of a matrix to

- cover large chondral defect during microfracture. *Arthroscopy* 2009, 25:1354-1360
12. ERGGELET C, ENDRES M, NEUMANN K, MORAWIETZ L, RINGE J, HABERSTROH K, SITTINGER M, KAPS C: Formation of cartilage repair tissue in articular cartilage defects pretreated with microfracture and covered with cell-free polymer-based implants. *J Orthop Res* 2009, 27:1353-1360
13. ERGGELET C, NEUMANN K, ENDRES M, HABERSTROH K, SITTINGER M, KAPS C: Regeneration of ovine articular cartilage defects by cell-free polymer-based implants. *Biomaterials* 2007, 28:5570-5580
14. DEFRERE J, FRANCKART A: Teflon/polyurethane arthroplasty of the knee: the first 2 years preliminary clinical experience in a new concept of artificial resurfacing of full thickness cartilage lesions of the knee. *Acta Chir Belg* 1992, 92:217-227
15. VERDONK P, BEAUFILS P, BELLEMANS J, DJIAN P, HEINRICHS EL, HUYSSSE W, LAPRELL H, SIEBOLD R, VERDONK R: Actifit Study Group. Successful treatment of painful irreparable partial meniscal defects with a polyurethane scaffold: two-year safety and clinical outcomes. *Am J Sports Med* 2012, 40:844-853
16. FOSTER TE, PUSKAS BL, MANDELBAUM BR, GERHARDT MB, RODEO SA: Platelet-rich plasma: From basic science to clinical applications. *Am J Sports Med* 2009, 37:2259-2272
17. ZIMMERMANN R, RESKE S, METZLER P, SCHLEGEL A, RINGWALD J, Eckstein R: Preparation of highly concentrated and white cell-poor platelet-rich plasma by platelepheresis. *Vox Sang* 2008, 95:20-25
18. KON E, BUDA R, FILARDO G, DI MARTINO A, TIMONCINI A, CENACCHI A, FORNASARI PM, GIANNINI S, MARCACCI M: Platelet-rich plasma: intra-articular knee injections produced favorable results on degenerative cartilage lesions. *Knee Surg Sports Traumatol Arthrosc* 2010, 18:472-479
19. COLLINS NJ1, MISRA D, FELSON DT, CROSSLEY KM, ROOS EM: Measures of knee function. *Arthritis Care Res (Hoboken)* 2011, 63:208-228
20. IRRGANG JJ, ANDERSON AF, BOLAND AL, HARNER CD, KUROSAKA M, NEYRET P, RICHMOND JC, SHELBORNE KD: Development and validation of the international knee documentation committee subjective knee form. *Am J Sports Med* 2001, 29:600-613
21. CRAWFORD K, BRIGGS KK, RODKEY WG, STEADMAN JR: Reliability, validity, and responsiveness of the IKDC score for meniscus injuries of the knee. *Arthroscopy* 2007, 23:839-844
22. GOBBI A1, FRANCISCO R: Factors affecting return to sports after anterior cruciate ligament reconstruction with patellar tendon and hamstring graft: a prospective clinical investigation. *Knee Surg Sports Traumatol Arthrosc* 2006, 14:1021-1028
23. HAMBLY K, GRIVA K: IKDC or KOOS: which one captures symptoms and disabilities most important to patients who have undergone initial anterior cruciate ligament reconstruction? *Am J Sports Med* 2010, 38:1395-1404
24. BREIVIK H, BORCHGREVINK PC, ALLEN SM, ROSSELAND LA, ROMUNDSTAD L, HALS EK, KVARSTEIN G, STUBHAUG A: Assessment of pain. *Br J Anaesth* 2008, 101:17-24
25. SICLARI A, MASCARO G, GENTILI C, CANCEDDA R, BOUX E: A cell-free scaffold-based cartilage repair provides improved function hyaline-like repair at one year. *Clin Orthop Relat Res* 2012, 470:910-919.
26. TATU R, F, IVASCHESCU V, BOJIN F, HURMUZ M., TATU C., A Mechanical Vibration Method Used to Investigate the Evolution of Fractures Fixed with Biocompatible Materials, *Mat.Plast*, **51**, no.1, 2014, p.29
27. TATU R, F, IVASCHESCU V, BOJIN F, HURMUZ M., TATU C., PUSCASIU D., SISU A., Vibration Behaviour of Bone Fractures Fixed with Biocompatible Material Plates, *Mat.Plast.*, **50**, no.4, 2013, p.269
28. GHIBAN, N., BORTUN, M., BORDEASU, I., GHIBAN, B., FAUR, N., CERNESCU, A., Evaluation of mechanical properties by stereo- and scanning electron microscopy of some heat curing dental resins, *Mat.Plast.*, **47**, no.2, 2010, p.240

Manuscript received: 13.01.2016